

Chest computed tomography findings in hospitalized COVID-19 patients: a systematic review and meta-analysis

Syed Zaki Muhammad¹, Areeba Ahmed¹, Izza Shahid², Abdullah Khalid³, Ritesh G. Menezes⁴, Muhammad Usman Sheikh⁵, Tariq Jamal Siddiqi¹, Muhammad Shariq Usman¹, Faisal Khosa⁶

¹Department of Internal Medicine, Dow University of Health Sciences, Karachi, Pakistan;

²Department of Internal Medicine, Ziauddin Medical University, Karachi, Pakistan;

³Department of Medicine, Baqai Medical University, Karachi, Pakistan;

⁴Department of Pathology, College of Medicine, King Fahd Hospital of the University, Imam Abdulrahman Bin Faisal University, Dammam, Saudi Arabia;

⁵Department of Medicine, John H. Stroger, Jr. Hospital of Cook County, Chicago, IL, USA;

⁶Department of Radiology, University of British Columbia, Vancouver, Canada

SUMMARY

Most studies evaluating chest computed tomography (CT) features in coronavirus disease 2019 (COVID-19) have been small-sized and have presented varied findings. We aim to systematically review these studies and to conduct a meta-analysis of their results to provide a well-powered assessment of chest CT findings in patients with COVID-19. PubMed and EMBASE databases were systematically searched to identify published studies that evaluated chest CT findings in COVID-19 patients. Data regarding study characteristics and CT findings, including distribution of lesions, the lobe of lung involved, lesion densities, and radiological patterns, were extracted. Arcsine transformed proportions from individual studies were pooled using a random-effects model to derive pooled proportions (PPs) and 95% confidence intervals (CIs). A total of fifty-four studies (n=2693 confirmed COVID-19 patients) were

included in the final review. Prevalence of different CT findings varied across studies; however, the most common findings were bilateral pulmonary involvement (PP: 74.1% [68.4%, 79.5%]; $I^2=85.76\%$), ground glass opacification (PP: 64.6% [57.6%, 71.4%]; $I^2=91.52\%$), involvement of the left lower lobe (PP: 71.2% [58.9%, 82.1%]; $I^2=90.91\%$), and subpleural distribution of lesions (PP: 57.2% [39.0%, 74.3%]; $I^2=93.08\%$). Multivariate meta-regression revealed a positive association between prevalence of air bronchograms and average age of the population ($p=0.013$). Bilateral ground glass opacification, a subpleural distribution of lesions, and involvement of the left lower lobe were the most notable chest CT findings in COVID-19 patients.

Keywords: COVID-19, SARS-CoV-2, chest computed tomography, ground glass opacities.

INTRODUCTION

The current pandemic of Coronavirus Disease 2019 (COVID-19), caused by Severe Acute Respiratory Syndrome Coronavirus 2 (SARS-CoV-2), is responsible for a critical and acute respiratory condition in some patients [1, 2]. By May 2020, more than 2 million cases have been reported worldwide, with more than 120,000 reported

deaths [3]. Currently, nucleic acid testing by Reverse Transcription-Polymerase Chain Reaction (RT-PCR) is considered the gold standard for diagnosing COVID-19. However, this test produces a considerable number of false negatives [4]. High false negatives can lead to misdiagnosis, especially during initial stages where adequate treatment and isolation can help limit disease severity and prevent spread [5].

It has been shown that chest computed tomography (CT) imaging can show typical radiological findings of COVID-19 even before the onset of clinical symptoms [6-8]. It has helped clinicians to

Corresponding author

Faisal Khosa

E-mail: fkhosa@gmail.com

identify COVID-19 patients who initially had negative RT-PCR results [6, 9]. Although several observational studies reporting chest CT findings in COVID-19 patients have been published, most have small patient numbers and varied conclusions regarding the most common CT manifesta-

tions of COVID-19. Therefore, we sought to perform a systematic review and meta-analysis of these studies, in an attempt to produce well-powered summary estimates which are generalizable across COVID-19 patients.

Table 1 - Pooled prevalence of chest CT findings (distribution of lesions, lobe involvement, lesion densities, and patterns) in confirmed COVID-19 patients.

Variable	Number of patients affected	Total number of patients	Pooled percentages % (95% CI, %)	Heterogeneity
<i>Distribution of lesion</i>				
Bilateral	1411	1937	74.1 (68.4 - 79.5)	85.76
Subpleural	299	509	57.2 (39.0 - 74.3)	93.08
Peripheral	770	1287	57.1 (46.7 - 67.1)	92.42
Posterior	44	69	37.9 (1.5 - 87.2)	92.38
Unilateral	216	1048	20.5 (15.0 - 26.6)	77.48
Central	47	551	8.9 (3.1 - 17.2)	87.84
<i>Lobe involvement</i>				
LLL	500	696	71.2 (58.9 - 82.1)	90.91
RLL	504	710	66.5 (53.4 - 78.5)	91.45
LUL	403	681	57.2 (44.4 - 69.4)	90.39
RUL	385	690	53.1 (41.8 - 64.2)	87.66
RML	345	736	42.8 (29.1 - 57.1)	93.24
<i>Lesion density</i>				
GGO	1541	2416	64.6 (57.6 - 71.4)	91.52
Mixed	524	1176	43.0 (36.8 - 49.3)	72.56
Consolidation	615	2037	27.7 (19.1 - 37.1)	95.19
<i>Patterns</i>				
Vascular changes	312	441	62.9 (45.7 - 78.5)	91.75
Septal thickening	399	846	40.6 (28.2 - 53.7)	92.74
Air bronchogram	491	1199	39.7 (29.1 - 50.9)	93.26
Fibrosis/stripes	200	562	37.2 (21.7 - 54.1)	93.98
Crazy paving pattern	350	1181	29.0 (19.0 - 40.1)	93.68
Halo sign	110	380	27.3 (8.8 - 51.2)	95.29
Spider web design	45	195	22.3 (15.6 - 29.9)	30.55
Bronchial wall thickening	100	509	19.4 (13.4 - 26.3)	70.88
Subpleural lines	117	698	15.0 (7.2 - 25.1)	90.81
Nodules	95	918	11.2 (6.5 - 17.0)	83.28
Pleural effusion	108	1784	5.8 (4.1 - 7.7)	62.31
Lymphadenopathy	65	1193	5.3 (2.9 - 8.4)	78.11
Pericardial effusion	13	394	3.0 (1.3 - 5.4)	33.16

LLL: left lower lobe, RLL: right lower lobe, LUL: left upper lobe, RUL: right upper lobe, RML: right middle lobe, GGO: ground glass opacification.

METHODS

This study has been reported in concordance with guidelines provided by the Preferred Reporting Items for Systematic review and Meta-Analyses (PRISMA) [10]. PubMed and EMBASE databases were systematically searched by two independent investigators (SZM and AA) in May 2020. No time or language restrictions were set. All articles retrieved from the initial search were transferred to Endnote Reference Library (Version X9; Clarivate Analytics, Philadelphia, Pennsylvania), where duplicates were identified and removed. Each investigator independently evaluated remaining articles by screening the title and abstract for relevance, followed by reading the full-text to confirm eligibility. The studies were eligible for inclusion if:

- 1) the full-text paper was available;
- 2) the study included patients with confirmed COVID-19;
- 3) reported CT findings.

All editorials and commentaries were excluded. Data regarding study characteristics and CT findings were extracted by two independent investigators (SZM and AA), and discrepancies were solved by discussion and consensus. The follow-

ing information was extracted: country, study type, sample size, age, and sex. Outcomes of interest regarding CT findings included: distribution of lesion, the lobe of lung involved, lesion densities, and the radiological patterns.

OpenMetaAnalyst was used to perform statistical analysis [11]. The CT findings reported in more than one study were presented as proportions. Proportions were subjected to arcsine transformation to stabilize the variance, so that unnecessary weights are avoided for studies with small or large prevalence [12]. Arcsine transformed proportions and corresponding 95% confidence intervals (CIs) from individual studies were pooled using a random-effects model. A p -value <0.05 was considered significant. The heterogeneity was assessed using the I^2 statistics, and a value $>75\%$ was considered as significant [13].

RESULTS

The initial search yielded 759 potential studies. After exclusions based on title and abstract ($n=607$), we screened 152 full-text studies, of which 54 studies (43 retrospective studies and 11 case series and case reports) were included in the

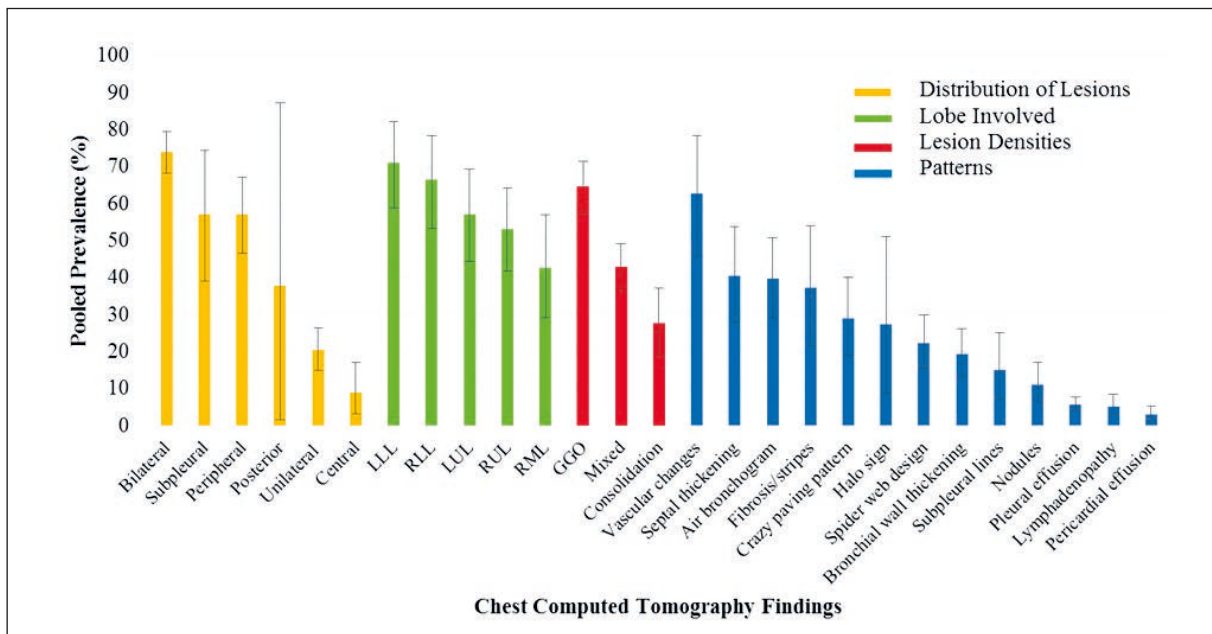


Figure 1 - Bar chart showing the pooled prevalence of chest CT findings (distribution of lesions, lobe involvement, lesion densities, and patterns) with 95% confidence intervals.

LLL: left lower lobe, RLL: right lower lobe, LUL: left upper lobe, RUL: right upper lobe, RML: right middle lobe, GGO: ground glass opacification.

final review [14-67]. These included a total of 2693 confirmed COVID-19 patients. Forty-four studies, including a total of 2676 patients, were meta-analyzed. The remaining ten studies were not included in the meta-analysis due to small sample size (<5 patients) and a high risk of bias; however, they have been included in the qualitative review. Upon meta-analysis, the pooled prevalence of male gender in our population was 52.6% (95% CI 48.8%, 56.4%; $I^2=66.78\%$).

The imaging manifestations varied across patients, but the most common findings were bilateral pulmonary involvement (PP: 74.1% [68.4%, 79.5%]; $I^2=85.76\%$), involvement of left lower lobe (PP: 71.2% [58.9%, 82.1%]; $I^2=90.91\%$), ground glass opacification (GGO) (PP: 64.6% [57.6%, 71.4%]; $I^2=91.52\%$), and subpleural distribution of lesions (PP: 57.2% [39.0%, 74.3%]; $I^2=93.08\%$). The imaging manifestations are detailed in Table 1 and Figure 1. Multivariate meta-regression revealed that the prevalence of air bronchograms had a significant positive correlation with the age of the patients ($p=0.013$); however, no other CT finding showed such a relation.

■ DISCUSSION

This systematic review and meta-analysis provides a comprehensive overview of the most notable findings on chest CT in a large cohort of COVID-19 patients. Our pooled analysis of 44 studies demonstrated GGO as the most common lesion density. Lesions were particularly evident in the left lower lobe of the lung, mostly bilateral or subpleural in distribution. The most frequent patterns observed were vascular changes, septal thickening, and air bronchograms, while mediastinal lymphadenopathy, pleural effusion, and pericardial effusion were rarely detected. The prevalence of majority of the findings on chest CT did not vary significantly according to the average age, suggesting that these findings might be found across all age groups.

Our results are consistent with previous studies, which similarly reported GGO with bilateral pulmonary involvement as the predominant CT manifestation, even in asymptomatic cases of COVID-19 patients [1, 2, 68]. The early appearance of GGO in chest CT can be due to its pathophysiology. After inhalation, the SARS-CoV-2 virus invades the pulmonary interstitium at the end

of the lobular bronchioles spreading to the distal end. The lesion originates in the secondary pulmonary lobule, initially appearing as a round ground-glass appearance on CT, and then expands to appear as confluent GGO [68].

Our results show the left lower lobe of the lung as the most commonly involved pulmonary lobe. Contradictory results have been observed, with multiple studies reporting the right lower lobe more frequently involved [17, 29, 30, 32, 41, 45]. Our results also contrast with the earlier reported SARS virus, where severe consolidation was reported more frequently in the right lung [69, 70]. Moreover, prior studies reported patterns such as pleural effusion and lymphadenopathy to appear on chest CT [25, 52]. Our results, however, conclude vascular changes, septal thickening, and air bronchogram to be the most frequently observed patterns.

Patients with severe disease were generally older and had more underlying health conditions than patients with milder forms [25, 35, 41]. Two studies showed consolidation and bilateral infiltration to be more frequent in patients who died from COVID-19 than patients who survived the disease [56, 57].

This study has a few limitations which should be considered. First, this meta-analysis included observational studies, and findings were not adjusted for baseline characteristics and comorbidities, thus, confounding bias is a possibility. Second, some outcomes had high unexplained statistical heterogeneity. We believe this is likely due to the inclusion of mainly small sized studies, which often produce results that vary around the mean value. Heterogeneity could also be due to differences in patient populations and study settings. Third, it must be noted that study-level meta-regression is mainly exploratory and is prone to ecological bias. Last, while this study provides early insight into CT characteristics of COVID-19 patients, it should not be considered a replacement for large-scale observational studies that are currently awaited.

■ CONCLUSION

Our systematic review and meta-analysis highlight the prevalence of characteristic CT findings in hospitalized COVID-19 patients. Bilateral ground glass opacification, commonly involving the left

lower lobe, with a subpleural distribution of lesions, were the most predominant manifestation. Common patterns on CT included vascular signs, septal thickening, and air bronchograms. Both the increasing prevalence of COVID-19 and the questionable sensitivity of RT-PCR have likely resulted in a low negative predictive value of this test. This makes awareness of salient CT features of COVID-19 essential for practicing physicians. Identification of these CT features, in conjunction with a classic clinical presentation, can enable physicians to have a high suspicion for COVID-19 in cases where RT-PCR produces a false-negative result.

Funding

None.

Disclosures

Dr. Khosa is the recipient of the National Association of Faculties of Medicine of Canada - May Cohen Equity, Diversity, and Gender Award (2020). Other authors have no relevant disclosures.

REFERENCES

- [1] Rodriguez-Morales AJ, Cardona-Ospina JA, Gutierrez-Ocampo E, et al. Clinical, laboratory and imaging features of COVID-19: A systematic review and meta-analysis. *Travel Med and Infect Dis.* 2020; 34, 101623.
- [2] Salehi S, Abedi A, Balakrishnan S, Gholamrezaezhad A. Coronavirus disease 2019 (COVID-19): a systematic review of imaging findings in 919 patients. *Am J Roentgenol.* 2020; 215 (1), 87-93.
- [3] Dong E, Du H, Gardner L. An interactive web-based dashboard to track COVID-19 in real time. *Lancet Infect Dis.* 2020; 20 (5), 533-4.
- [4] Pan Y, Li X, Yang G, et al. Serological immunochromatographic approach in diagnosis with SARS-CoV-2 infected COVID-19 patients. *J Infect.* 2020; 81 (1), e28-e32.
- [5] Hope MD, Raptis CA, Shah A, Hammer MM, Henry TS. A role for CT in COVID-19? What data really tell us so far. *Lancet.* 2020; 395 (10231), 1189-90.
- [6] Ai T, Yang Z, Hou H, et al. Correlation of chest CT and RT-PCR testing in coronavirus disease 2019 (COVID-19) in China: a report of 1014 cases. *Radiology.* 2020; 296 (2), E32-40.
- [7] Pan Y, Guan H, Zhou S, et al. Initial CT findings and temporal changes in patients with the novel coronavirus pneumonia (2019-nCoV): a study of 63 patients in Wuhan, China. *Eur Radiol.* 2020; 30 (6), 3306-9.
- [8] Kim JY, Choe PG, Oh Y, et al. The first case of 2019 novel coronavirus pneumonia imported into Korea from Wuhan, China: implication for infection prevention and control measures. *J Korean Med Sci.* 2020; 35 (5), e61.
- [9] Huang P, Liu T, Huang L, et al. Use of chest CT in combination with negative RT-PCR assay for the 2019 novel coronavirus but high clinical suspicion. *Radiology.* 2020; 295 (1), 22-23.
- [10] Liberati A, Altman D, Tetzlaff J, et al. The PRISMA statement for reporting systematic reviews and meta-analyses of studies that evaluate healthcare interventions: explanation and elaboration. *BMJ.* 2009; 339, b2700.
- [11] Wallace BC, Dahabreh IJ, Trikalinos TA, Lau J, Trow P, Schmid CH. Closing the gap between methodologists and end-users: R as a computational back-end. *J Stat Softw.* 2012; 49 (5), 1-5.
- [12] Barendregt JJ, Doi SA, Lee YY, Norman RE, Vos T. Meta-analysis of prevalence. *J Epidemiol Community Health.* 2013; 67 (11), 974-8.
- [13] Higgins JP, Thompson SG, Deeks JJ, Altman DG. Measuring inconsistency in meta-analyses. *BMJ.* 2003; 327 (7414), 557-60.
- [14] Wang K, Kang S, Tian R, Zhang X, Wang Y. Imaging manifestations and diagnostic value of chest CT of coronavirus disease 2019 (COVID-19) in the Xiaogan area. *Clin Radiol.* 2020; 75 (5), 341-7.
- [15] Han R, Huang L, Jiang H, Dong J, Peng H, Zhang D. Early clinical and CT manifestations of coronavirus disease 2019 (COVID-19) pneumonia. *Am J Roentgenol.* 2020; doi: 10.2214/AJR.20.22961.
- [16] Wu J, Feng CL, Xian XY, et al. Novel coronavirus pneumonia (COVID-19) CT distribution and sign features. *Zhonghua Jie He He Hu Xi Za Zhi.* 2020; 43 (4), 321-6.
- [17] Bernheim A, Mei X, Huang M, et al. Chest CT findings in coronavirus disease-19 (COVID-19): relationship to duration of infection. *Radiology.* 2020; 295 (3), 200463.
- [18] Wang D, Ju XL, Xie F, et al. Clinical analysis of 31 cases of 2019 novel coronavirus infection in children from six provinces (autonomous region) of northern China. *Zhonghua Er Ke Za Zhi.* 2020; 58 (4), 269-74.
- [19] Xie X, Zhong Z, Zhao W, Zheng C, Wang F, Liu J. Chest CT for typical 2019-nCoV pneumonia: relationship to negative RT-PCR testing. *Radiology.* 2020; 296 (2), E41-5.
- [20] Qiu H, Wu J, Hong L, Luo Y, Song Q, Chen D. Clinical and epidemiological features of 36 children with coronavirus disease 2019 (COVID-19) in Zhejiang, China: an observational cohort study. *Lancet Infect Dis.* 2020; 20 (6), 689-96.
- [21] Zheng F, Liao C, Fan QH, et al. Clinical characteristics of children with coronavirus disease 2019 in Hubei, China. *Curr Med Sci.* 2020; 40 (2), 275-80.
- [22] Sun D, Li H, Lu XX, et al. Clinical features of severe pediatric patients with coronavirus disease 2019 in Wuhan: a single center's observational study. *World J Pediatr.* 2020; 16 (3), 251-9.
- [23] Liu KC, Xu P, Lv WF, Qiu XH, Yao JL, Jin-Feng G.

- CT manifestations of coronavirus disease-2019: A retrospective analysis of 73 cases by disease severity. *Eur J Radiol.* 2020; 126, 108941.
- [24] Chen S, Liao E, Cao D, Gao Y, Sun G, Shao Y. Clinical analysis of pregnant women with 2019 novel coronavirus pneumonia. *J Med Virol.* 2020; doi: 10.1002/jmv.25789.
- [25] Li K, Wu J, Wu F, et al. The clinical and chest CT features associated with severe and critical COVID-19 pneumonia. *Invest Radiol.* 2020; 55 (6), 327-31.
- [26] Chu J, Yang N, Wei Y, et al. Clinical characteristics of 54 medical staff with COVID-19: A retrospective study in a single center in Wuhan, China. *J Med Virol.* 2020; 92 (7), 807-13.
- [27] Li M, Lei P, Zeng B, et al. Coronavirus disease (COVID-19): spectrum of CT findings and temporal progression of the disease. *Acad Radiol.* 2020; 27 (5), 603-8.
- [28] Guan CS, Lv ZB, Yan S, et al. Imaging features of coronavirus disease 2019 (COVID-19): evaluation on thin-section CT. *Acad Radiol.* 2020; 27 (5), 609-13.
- [29] Cheng Z, Lu Y, Cao Q, et al. Clinical features and chest CT manifestations of coronavirus disease 2019 (COVID-19) in a single-center study in Shanghai, China. *Am J Roentgenol.* 2020; 215 (1), 121-6.
- [30] Zhu Y, Gao ZH, Liu YL, et al. Clinical and CT imaging features of 2019 novel coronavirus disease (COVID-19). *J Infect.* 2020; 81 (1), 147-78.
- [31] Liu H, Liu F, Li J, Zhang T, Wang D, Lan W. Clinical and CT imaging features of the COVID-19 pneumonia: focus on pregnant women and children. *J Infect.* 2020; 80 (5), e7-e13.
- [32] Li Y, Xia L. Coronavirus Disease 2019 (COVID-19): role of chest CT in diagnosis and management. *Am J Roentgenol.* 2020; 214 (6), 1280-6.
- [33] Zhang S, Li H, Huang S, You W, Sun H. High-resolution CT features of 17 cases of Corona Virus Disease 2019 in Sichuan province, China. *Eur Respir J.* 2020; 55 (4), 2000334.
- [34] Xiong Y, Sun D, Liu Y, et al. Clinical and High-Resolution CT Features of the COVID-19 infection: comparison of the initial and follow-up changes. *Invest Radiol.* 2020; 55 (6), 332-9.
- [35] Song F, Shi N, Shan F, et al. Emerging 2019 novel coronavirus (2019-nCoV) pneumonia. *Radiology.* 2020; 295 (1), 210-7.
- [36] Shi F, Yu Q, Huang W, Tan C. 2019 Novel coronavirus (COVID-19) pneumonia with hemoptysis as the initial symptom: CT and clinical features. *Korean J Radiol.* 2020; 21 (5), 537-40.
- [37] Albarello F, Pianura E, Di Stefano F, et al. 2019-novel Coronavirus severe adult respiratory distress syndrome in two cases in Italy: an uncommon radiological presentation. *Int J Infect Dis.* 2020; 93, 192-7.
- [38] Zhou S, Wang Y, Zhu T, Xia L. CT features of coronavirus disease 2019 (COVID-19) pneumonia in 62 patients in Wuhan, China. *Am J Roentgenol.* 2020; 214 (6), 1287-94.
- [39] Xia W, Shao J, Guo Y, Peng X, Li Z, Hu D. Clinical and CT features in pediatric patients with COVID-19 infection: Different points from adults. *Pediatr Pulmonol.* 2020; 55 (5), 1169-74.
- [40] Shi H, Han X, Jiang N, et al. Radiological findings from 81 patients with COVID-19 pneumonia in Wuhan, China: a descriptive study. *Lancet Infect Dis.* 2020; 20 (4), 425-34.
- [41] Xu YH, Dong JH, An WM, et al. Clinical and computed tomographic imaging features of novel coronavirus pneumonia caused by SARS-CoV-2. *J Infect.* 2020; 80 (4), 394-400.
- [42] Guan W, Liu J, Yu C. CT Findings of coronavirus disease (COVID-19) severe pneumonia. *Am J Roentgenol.* 2020; 214 (5), W85-86.
- [43] Han X, Fan Y, Wan YL, Shi H. A Diabetic Patient With 2019-nCoV (COVID-19) Infection who recovered and was discharged from hospital. *J Thorac Imaging.* 2020; 35 (3), W94-W95.
- [44] Liao X, Yang H, Kong J. Chest CT Findings in a pregnant patient with 2019 novel coronavirus disease. *Balkan Med J.* 2020; 37 (4), 226-8.
- [45] Xu X, Yu C, Qu J, et al. Imaging and clinical features of patients with 2019 novel coronavirus SARS-CoV-2. *Eur J Nucl Med Mol Imaging.* 2020; 47 (5), 1275-80.
- [46] Lin C, Ding Y, Xie B, et al. Asymptomatic novel coronavirus pneumonia patient outside Wuhan: The value of CT images in the course of the disease. *Clin Imaging.* 2020; 63, 7-9.
- [47] Lin X, Gong Z, Xiao Z, Xiong J, Fan B, Liu J. Novel coronavirus pneumonia outbreak in 2019: computed tomographic findings in two cases. *Korean J Radiol.* 2020; 21 (3), 365-8.
- [48] Zhou Z, Guo D, Li C, et al. Coronavirus disease 2019: initial chest CT findings. *Eur Radiol.* 2020; 30 (8), 4498-506.
- [49] Su L, Ma X, Yu H, et al. The different clinical characteristics of corona virus disease cases between children and their families in China—the character of children with COVID-19. *Emerg Microbes Infect.* 2020; 9 (1), 707-13.
- [50] Zhu W, Xie K, Lu H, Xu L, Zhou S, Fang S. Initial clinical features of suspected Coronavirus Disease 2019 in two emergency departments outside of Hubei, China. *J Med Virol.* 2020; doi: 10.1002/jmv.25763.
- [51] Li W, Cui H, Li K, Fang Y, Li S. Chest computed tomography in children with COVID-19 respiratory infection. *Pediatr Radiol.* 2020; 50 (6), 796-99.
- [52] Wu J, Wu X, Zeng W, et al. Chest CT findings in patients with coronavirus disease 2019 and its relationship with clinical features. *Invest Radiol.* 2020; 55 (5), 257-61.
- [53] Zhang X, Song W, Liu X, Lyu L. CT image of novel coronavirus pneumonia: a case report. *Jpn J Radiol.* 2020; 38, 407-8.
- [54] Li CX, Wu B, Luo F, Zhang N. Clinical study and CT findings of a familial cluster of pneumonia with

- coronavirus disease 2019 (COVID-19). *J Sichuan Univer. Medical Science Edition*. 2020; 51 (2), 155-8.
- [55] Lu T, Pu H. Computed tomography manifestations of 5 cases of the novel coronavirus disease 2019 (COVID-19) pneumonia from patients outside Wuhan. *J Thorac Imaging*. 2020; 35 (3), W90-W93.
- [56] Zhou F, Yu T, Du R, et al. Clinical course and risk factors for mortality of adult inpatients with COVID-19 in Wuhan, China: a retrospective cohort study. *Lancet*. 2020; 395 (10229), 1054-62.
- [57] Yuan M, Yin W, Tao Z, Tan W, Hu Y. Association of radiologic findings with mortality of patients infected with 2019 novel coronavirus in Wuhan, China. *PLoS One*. 2020; 15 (3), e0230548.
- [58] Xu X, Yu C, Qu J, et al. Imaging and clinical features of patients with 2019 novel coronavirus SARS-CoV-2. *Eur J Nucl Med Mol Imaging*. 2020; 47 (5), 1275-80.
- [59] Zhao W, Zhong Z, Xie X, Yu Q, Liu J. Relation between chest CT findings and clinical conditions of coronavirus disease (COVID-19) pneumonia: a multicenter study. *Am J Roentgenol*. 2020; 214 (5), 1072-77.
- [60] Dai WC, Zhang HW, Yu J, et al. CT imaging and differential diagnosis of COVID-19. *Can Assoc Radiol J*. 2020; 71 (2), 195-200.
- [61] Yang W, Cao Q, Qin L, et al. Clinical characteristics and imaging manifestations of the 2019 novel coronavirus disease (COVID-19): a multi-center study in Wenzhou city, Zhejiang, China. *J Infect*. 2020; 80 (4), 388-93.
- [62] Fan N, Fan W, Li Z, Shi M, Liang Y. Imaging characteristics of initial chest computed tomography and clinical manifestations of patients with COVID-19 pneumonia. *Jpn J Radiol*. 2020; 38 (6), 533-8.
- [63] Lomoro P, Verde F, Zerboni F, et al. COVID-19 pneumonia manifestations at the admission on chest ultrasound, radiographs, and CT: single-center study and comprehensive radiologic literature review. *Eur J Radiol Open*. 2020; doi: 10.1016/j.ejro.2020.100231.
- [64] Miao C, Jin M, Miao L, et al. Early chest computed tomography to diagnose COVID-19 from suspected patients: A multicenter retrospective study. *Am J Emerg Med*. 2020; doi: 10.1016/j.ajem.2020.04.051.
- [65] Zhong Z, Xie X, Huang W, Zhao W, Yu Q, Liu J. Chest CT findings and clinical features of coronavirus disease 2019 in children. *Zhong Nan Da Xue Xue Bao Yi Xue Ban*. 2020; 45 (3), 236-42.
- [66] Huang R, Zhu L, Xue L, et al. Clinical findings of patients with coronavirus disease 2019 in Jiangsu Province, China: A Retrospective, Multi-Center Study. *PLoS Negl Trop Dis*. 2020; 14 (5), e0008280.
- [67] Wong HY, Lam HY, Fong AH, et al. Frequency and distribution of chest radiographic findings in COVID-19 positive patients. *Radiology*. 2020; 296 (2), E72-8.
- [68] Meng H, Xiong R, He R, et al. CT imaging and clinical course of asymptomatic cases with COVID-19 pneumonia at admission in Wuhan, China. *J Infect*. 2020; 81 (1), E33-9.
- [69] Goh JS, Tsou IY, Kaw GJ. Severe acute respiratory syndrome (SARS): imaging findings during the acute and recovery phases of disease. *J Thorac Imaging*. 2003; 18 (3), 195-9.
- [70] Wong KT, Antonio GE, Hui DS, et al. Severe acute respiratory syndrome: radiographic appearances and pattern of progression in 138 patients. *Radiology*. 2003; 228 (2), 401-6.