

# Multiple chronic parasitic infections in an immunocompetent immigrant: a challenge for healthcare management

Chiara Spertilli Raffaelli<sup>1</sup>, Barbara Rossetti<sup>2</sup>, Lorenzo Zammarchi<sup>3,4</sup>, David Redi<sup>1</sup>, Francesca Rinaldi<sup>3</sup>, Andrea De Luca<sup>1,2</sup>, Francesca Montagnani<sup>1,2</sup>

<sup>1</sup>Dipartimento di Biotecnologie Mediche, Università di Siena, Siena, Italy;

<sup>2</sup>UOC Malattie Infettive Universitarie, AOUS, Siena, Italy;

<sup>3</sup>Dipartimento di Medicina Sperimentale e Clinica, Università degli Studi di Firenze, Florence, Italy;

<sup>4</sup>SOD Malattie Infettive e Tropicali, AOUC, Florence, Italy

## SUMMARY

The case reports multiple helminthiasis and chronic hepatitis caused by hepatitis B virus (HBV)/hepatitis D virus (HDV) in an immunocompetent immigrant male. It highlights the importance of early diagnosis and treatment of neglected infectious diseases in low endemic ar-

eas, besides difficulties that Western countries encounter in responding to immigrants' health needs.

*Keywords:* parasitic infections, travel, migration, immigrants, neglected infectious diseases.

## INTRODUCTION

Immigrants in Western Europe represent a peculiar epidemiological setting, due to the possible presence of chronic and underdiagnosed infections [1].

Parasitic infections are a significant public health problem in tropical areas. Despite the existence of some foci of autochthonous transmission, these diseases disproportionately affect immigrants from tropical areas if compared with native and international travelers in temperate areas [2-3]. Chronic infestations are characterized by non-specific symptoms, often in combination with unexplained eosinophilia [4].

*Strongyloides stercoralis* can cause a lifelong asymptomatic infection, but it may progress to a hyperinfection/disseminated syndrome with a high fatality rate in immunosuppressed subjects

[5]. Besides parasitic infections, some reports from Southern Italy showed a high prevalence of HBV, HCV and HIV infection in recent immigrants, with higher prevalence in males from Sub-Saharan Africa especially in presence of risk factors [6, 7].

We report the difficult management of a case of multiple parasitic and viral infections in a young immunocompetent recently immigrated to Italy.

## CASE REPORT

In April 2016, a 20-years-old Nigerian man was hospitalized at the Infectious Diseases Unit of Siena Hospital. The patient had migrated to Italy from Libya 3 days before, reporting a previous 2 months stay in Libya and an unspecified abdominal surgery few months before. On admission, he complained fever and abdominal pain. At physical examination, mitral pansystolic murmur and tachypnea were observed without fever. The blood exams revealed hypereosinophilia (white blood cells 9,110/mm<sup>3</sup>, eosinophil cells 3,050/

*Corresponding author*

David Redi

E-mail: david.redi@yahoo.it

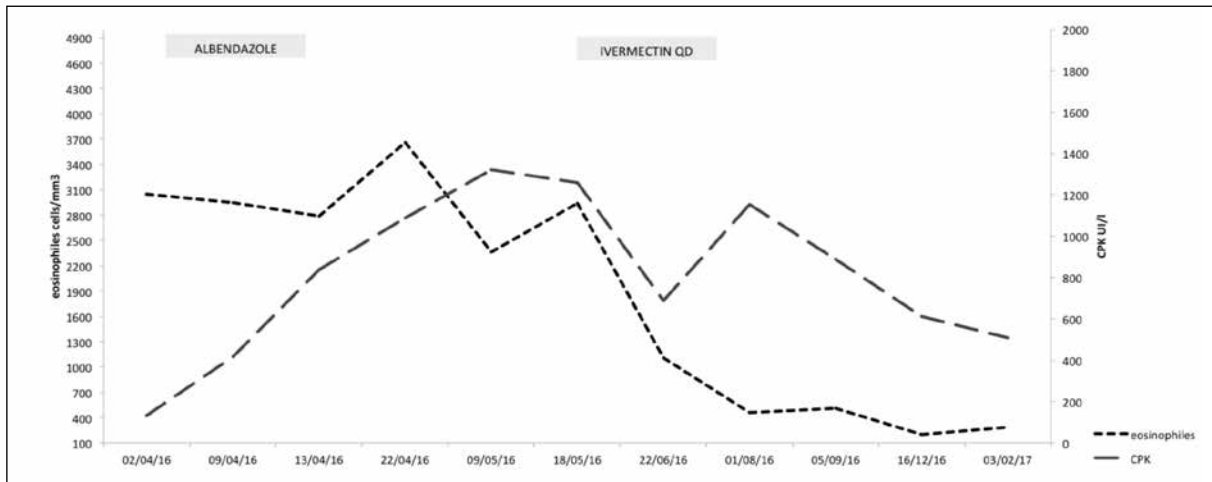


Figure 1 - Laboratory findings and therapeutic history.

mm<sup>3</sup>, [ULN 700/mm<sup>3</sup>]), microcytic hypochromic anaemia with normal iron status, hypertransaminasaemia (AST/ALT 102/195 IU/L, ULN 37/41 IU/L), high level of procalcitonin (3.38 ng/mL, ULN 0.5 ng/mL) and IgG monoclonal peak. During hospitalization, he presented high myoglobin and creatine-phosphokinase (CPK) levels (up to 837 UI/L [ULN <170 UI/L]) with a progressive worsening. Previously unknown hepatitis B virus and hepatitis D virus coinfection were also diagnosed. HBV-DNA was 1,447 IU/mL, HBeAg negative, anti-HBe and qualitative HDV-RNA positive. Hepatitis A virus serology documented a previous infection. Hepatitis C virus, Human Immunodeficiency Virus and lue serology were negative. An abdomen ultrasound revealed a hepatosplenomegaly and a liver inhomogeneous ultrasound structure, as for chronic hepatitis. The chest X-ray did not reveal any alteration. Repeated malaria tests were negative. Two over three parasitological stool examinations revealed the presence of rare hookworm *Ancylostoma/Necator* eggs: oral albendazole 400 mg/day was administered for three days.

After clinical improvement and normalization of procalcitonin levels, he was discharged with reducing eosinophils and CPK. In the next days, he reported raising abdominal pain, associated to persistent hypereosinophilia (3,160 cell/mm<sup>3</sup>), increasing CPK levels (up to 1,322 UI/L), myoglobin (max 339 ng/mL, UNL <72) and troponin (28 ng/L, UNL <15). Serum IgE increase with

doubtful positivity of immunoglobulin E specific for *Anisakis* spp. (0.42 kUA/L, ULN <0.1) was also observed. An upper digestive tract endoscopy showed an antral gastropathy; *Helicobacter pylori* was absent. An abdominal computerized tomography scan revealed only the presence of an umbilical hernia. As an echocardiogram revealed hypertensive cardiopathy, the patient started a therapy with valsartan 40 mg QD.

*Echinococcus*, *Toxocara*, *Filaria*, *Trichinella*, *Cysticercus*, HTLV 1-2, *Schistosoma* serology stool, agar plate culture for *Strongyloides* were negative. Serology for *S. stercoralis* resulted in IgG positivity (3.56 index, cut-off 1): the patient was treated with ivermectin 200 mcg/kg once orally. Since fatal encephalopathy is reported in patients with high *L. loa* microfilariae blood level treated with ivermectin, treatment was started after excluding *Loa loa* infestation. Ivermectin is not approved in Italy and it is not commonly available: the patient was referred to the Reference Centre for Tropical Diseases in Florence. Subsequent laboratory tests showed improved eosinophilia, CPK, myoglobin and troponin with complete remission of abdominal pain. Tissue examination from liver biopsy revealed a chronic hepatitis with lobular activity compatible with HBV/HDV hepatitis (grading 7, staging 4, Ishak score). In December 2016, he started entecavir 0,5 mg QD orally, achieving a persistently undetectable serum HBV-DNA. At 6th and 12th months after ivermectin treatment, *Strongyloides* serology was negative.

The laboratory test in July 2017 showed a normalization of the eosinophils count and troponin values and a reduction of CPK and myoglobin (Figure 1). The patient is actually asymptomatic.

## ■ DISCUSSION

Although multiple infections with the same or different parasites have been reported, simultaneous infections are rare even in the immigrant population. Recent significant migration flows from low-income countries and increasing travels prompt clinicians to revise the priorities of diagnostic suspicion. Parasitic infections can be found with increasing frequency in patients presenting to health services in Western countries [8]. Sometimes helminth infections simulate or require surgery and it is mandatory to consider them among differential diagnoses in immigrants from or travelers through endemic areas [9].

Despite recommendation for immigrants' care in Italy, the heterogeneity of clinical approach and the availability of diagnostic tests in different regions could have a negative impact on their clinical problems management [10].

Although in good clinical conditions, recent immigrants may carry asymptomatic or chronic infections and this can lead to an incomplete assessment of their health and result in a delayed diagnosis, even due to physicians limited awareness and knowledge regarding tropical diseases and the unavailability of diagnostic test [11].

In our case, after the first diagnosis of hookworm infection, physicians were quite comfortable to have completed diagnostic and therapeutic management. The persistence of hypereosinophilia and clinical symptoms led to a deeper diagnostic workout, but for the most common parasites tests were not currently available.

*Strongyloides* is a nematode parasite that globally affects more than 100 million individuals, not causing even hypereosinophilia. Clinical features most commonly include gastrointestinal symptoms like nausea, weight loss, abdominal pain and diarrhea. Moreover, immunocompromised patients with chronic infection due to *S. stercoralis* are at high risk of larval proliferation, with systemic dissemination and severe recurrent bacterial complications or sepsis due to intestinal translocation [2]. Diagnosis of *S. stercoralis* infection

requires dedicated techniques, such as blood agar plate culture of stool and serology since the direct stool parasitological examination is insensitive due to the low larval output [12].

The treatment choice of uncomplicated strongyloidiasis is ivermectin, that should be initiated to prevent parasite dissemination and hyperinfection [13-15]. Ivermectin is available in Italy only by import and difficulties in accessing the treatment have been reported in the clinical practice, leading to treatment failure with alternative antiparasitic agent [16].

The persistent increase of CPK remains to be completely understood. A recent study reports an unexpected high rate of rhabdomyolysis and persistently high plasma CPK levels in recent West African immigrants, suggesting exploring different causes especially travel conditions [17].

In conclusion, for multiple parasitic infections a combination of laboratory techniques is probably the best strategy to achieve the highest diagnostic sensitivity [12].

The data on HBV infection in immigrant population are scanty and the few available data support the need for Italian healthcare authorities to enhance screening of infectious diseases, mainly regarding hepatitis virus, HBV vaccination, treatment and educational programs for this high-risk population. Nevertheless, the high probability to observe multiple infections at once should lead to a wider parasitic screening in all immigrants, as recommended by national guidelines [10]. More epidemiological studies are needed in order to optimize the diagnostic flow, to improve the access to required treatments and to plan the necessary follow up of these cases. In the meanwhile, case reports may increase the awareness of physicians from low endemic countries about neglected parasitic infestations and to highlight the need to enhance the access to the necessary diagnostic and therapeutic resources.

## Conflict of interest

BR declares consultant fees from Janssen, ViiV Healthcare, Abbvie, MSD and Gilead, all outside the submitted work. DR received non-financial support from ViiV Healthcare, Abbvie, Astellas and Gilead, all outside the submitted work. ADL received unrestricted research grants from ViiV, Merck and Gilead (Fellowship Program) and was a paid consultant for ViiV, Merck and Gilead and

Janssen-Cilag, all outside the submitted work. FM received non-financial support from Angelini and Astellas, outside the submitted work, and was commissioned to do research for Novartis Vaccine and Diagnostic S.r.l. (now GSK Vaccine S.r.l.) on behalf of the University Hospital of Siena; she is Infectious Diseases Consultant for GSK (consultancy fee on behalf of University of Siena). None of the remaining authors have declared conflicts of interest.

## ■ REFERENCES

- [1] ASID-Australasian Society for Infectious Disease, RHeaNA-Refugee Health Network of Australia, 2016. Recommendations for comprehensive post-arrival health assessment for people from refugee-like backgrounds.
- [2] Buonfrate D., Angheben A., Gobbi F., et al. Imported strongyloidiasis: epidemiology, presentations, and treatment. *Curr. Infect. Dis. Rep.* 14, 256-262, 2012.
- [3] Silvestri C., Greganti G., Arzeni D., et al. Intestinal parasitosis: data analysis 2006-2011 in a teaching hospital of Ancona. *Infez. Med.* 21, 1, 34-39, 2013.
- [4] Baaten G.G., Sonder G.J., van Gool T., Kint J.A., van den Hoek A. Travel-related schistosomiasis, strongyloidiasis, filariasis, and toxocarasis: the risk of infection and the diagnostic relevance of blood eosinophilia. *BMC Infect. Dis.* 11, 84, 2011.
- [5] Buonfrate D., Requena-Mendez A., Angheben A., et al. Severe strongyloidiasis: a systematic review of case reports. *BMC Infect. Dis.* 13, 78, 2013.
- [6] Coppola N., Alessio L., Gualdieri L., et al. Hepatitis B virus infection in undocumented immigrants and refugees in Southern Italy: demographic, virological, and clinical features. *Infect. Dis. Poverty* 9, 6, 33, 2017.
- [7] Affronti M., Affronti A., Soresi M., et al. Distribution of liver disease in a cohort of immigrants in Sicily: analysis of day-hospital admissions in a migration medicine unit. *Infez. Med.* 22, 200-205, 2014.
- [8] Hotez P.J., Brindley P.J., Bethony J.M., King C.H., Pearce E.J., Jacobson J. Helminth infections: the great neglected tropical diseases. *J. Clin. Invest.* 118, 1311-1321, 2008.
- [9] Uysal E., Dokur M. The helminths causing surgical or endoscopic abdominal intervention: A review article. *Iran J. Parasitol.* 12, 156-168, 2017.
- [10] I controlli alla frontiera la frontiera dei controlli. Controlli sanitari all'arrivo e percorsi di tutela per i migranti ospiti nei centri di accoglienza. Linee guida salute migranti. Retrieved from [http://www.epicentro.iss.it/argomenti/migranti/pdf/LG\\_Migranti-web.pdf](http://www.epicentro.iss.it/argomenti/migranti/pdf/LG_Migranti-web.pdf). Last accessed May 14, 2018.
- [11] Grewal T., Azizi H., Kahn A., et al. A case of strongyloidiasis: an immigrant healthcare worker presenting with fatigue and weight loss. *Case Rep. Infect. Dis.* 6718284, 2017.
- [12] Requena-Méndez A., Chiodini P., Bisoffi Z., Buonfrate D., Gotuzzo E., Muñoz J. The laboratory diagnosis and follow up of strongyloidiasis: a systematic review. *PLoS Negl. Trop. Dis.* 7, e2002, 2013.
- [13] Hays R., Esterman A., McDermott R. Control of chronic *Strongyloides stercoralis* infection in an endemic community may be possible by pharmacological means alone: Results of a three-year cohort study. *PLoS Negl. Trop. Dis.* 31, 11, e0005825, 2017.
- [14] Suputtamongkol Y., Premasathian N., Bhummimuang K., et al. Efficacy and safety of single and double doses of ivermectin versus 7-day high dose albendazole for chronic strongyloidiasis. *PLoS Negl. Trop. Dis.* 5, e1044, 2011.
- [15] Bisoffi Z., Buonfrate D., Angheben A., et al. Randomized clinical trial on ivermectin versus thiabendazole for the treatment of strongyloidiasis. *PLoS Negl. Trop. Dis.* 5, e1254, 2011.
- [16] Zammarchi L., Montagnani F., Tordini G., et al. Persistent strongyloidiasis complicated by recurrent meningitis in an HTLV seropositive Peruvian migrant resettled in Italy. *Am. J. Trop. Med. Hyg.* 92, 1257-1260, 2015.
- [17] Odolini S., Gobbi F., Zammarchi L., et al. Febrile rhabdomyolysis of unknown origin in refugees coming from West Africa through the Mediterranean. *Int. J. Infect. Dis.* 62, 77-80, 2017.